

A Standardized Total Energy–Delivered Protocol Using Hybrid Radio Frequency for Treating Rhytides and Lax Skin

Victoria A. Cirillo-Hyland, MD

The Accent^{XL} radiofrequency (RF) device has been used successfully to treat rhytides and lax skin. Treatment protocols vary widely. Earlier studies used a timed number of passes over split treatment areas (eg, left cheek, right cheek, upper face, and lower face). In this study, we simplified and standardized the treatment protocol. We did not employ a timed number of passes, nor did we divide the face and neck into separate treatment areas; therefore, the face and neck were treated as one unit. Four patients were treated with the unipolar radiofrequency handpiece (110 kJ) and with the bipolar RF handpiece (50 kJ) on their faces and necks. Each patient received 4 treatments at 4- to 6-week intervals. Pre- and posttreatment clinical photographs (taken one month after the final treatment) and patient satisfaction ratings were used to assess treatment efficacy. Percentage results were measured based on subjective clinical improvement in rhytides and lax skin. One month after the final treatment, an independent physician-evaluator used clinical photographs to rate improvement. In patient 1 there was a 40% improvement; patient 2, a 45% improvement; patient 3, a 55% improvement; and patient 4, a 65% improvement. All patients rated their response as significantly improved. No adverse effects were reported. A standardized total energy–delivered protocol using hybrid RF safely and effectively treats rhytides and lax skin.

Radiofrequency (RF) devices have been used successfully to treat age-related rhytides and lax skin nonablatively.¹⁻³ Radio frequency is a form of electromagnetic energy with 3-MHz to 300-MHz frequencies. Within the RF field, RF devices generate heat from tissue resistance to electron movement.⁴⁻⁶ The Accent^{XL} RF device uses 2 RF handpieces

on a single platform. The unipolar handpiece delivers RF energy to a 10- to 20-mm depth, whereas the bipolar handpiece delivers RF energy to a 2- to 6-mm depth.

Accent^{XL} RF treatment protocols have been based on a timed number of passes over specific areas on the body once the targeted temperature of 40°C is achieved.^{1,3,7} We treated the faces and necks of 4 patients with a standardized total energy–delivered protocol. We did not use timed passes as part of our protocol. We treated the face and neck as a single treatment area.

Before treatment, baby oil was applied to the skin. The starting fluence of the unipolar handpiece was 100 W. The entire face and neck were treated continuously with circular, sweeping motions. Minimal pressure was

Dr. Cirillo-Hyland is Managing Partner, Bryn Mawr Skin & Cancer Institute, Pennsylvania, and Attending Dermatologist, Bryn Mawr Hospital.

Dr. Cirillo-Hyland is a consultant for Alma Lasers, Ltd.

Correspondence: Victoria A. Cirillo-Hyland, MD (drcirillo@brynmawrskinandcancer.com)

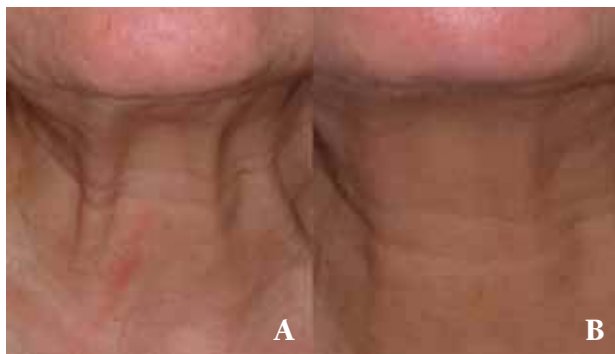


Figure 1. A 68-year-old patient before (A) and one month posttreatment with the Accent^{XL} radiofrequency device (B). An independent physician-evaluator noted a 40% clinical improvement.

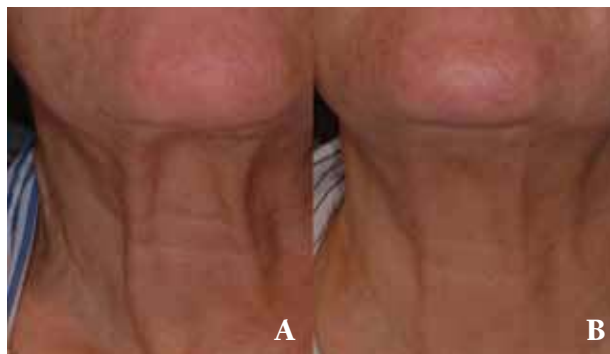

Figure 3. A 70-year-old patient before (A) and one month posttreatment with the Accent^{XL} radiofrequency device (B). An independent physician-evaluator noted a 55% clinical improvement.

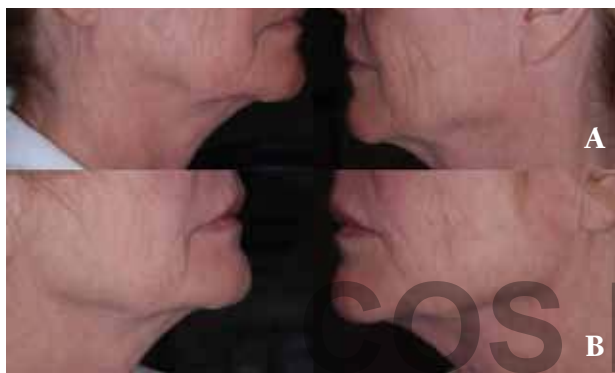

Figure 2. A 65-year-old patient before (A) and one month posttreatment with the Accent^{XL} radiofrequency device (B). An independent physician-evaluator noted a 45% clinical improvement.

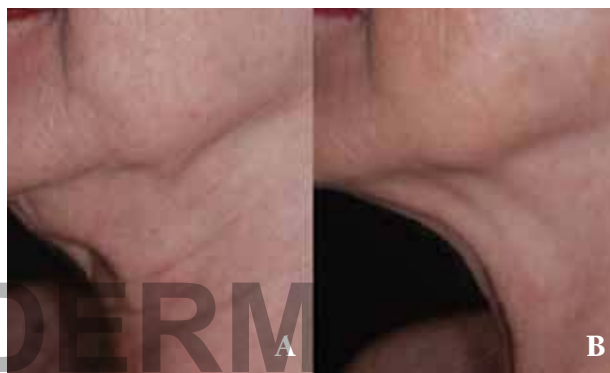

Figure 4. A 64-year-old patient before (A) and one month posttreatment with the Accent^{XL} radiofrequency device (B). An independent physician-evaluator noted a 65% clinical improvement.

applied to the handpiece, keeping it in direct contact with the skin. Care was taken to avoid the thyroid gland. The skin temperature was monitored using an infrared surface thermometer. Once the desired skin temperature of 40°C was achieved, the fluence was decreased to 95 W. Treatment continued until 110 kJ was delivered to the face and neck with the unipolar handpiece.

Treatment with the bipolar handpiece commenced immediately upon completion with the unipolar handpiece. The fluence of the bipolar handpiece was 60 W. A total of 50 kJ was delivered with the bipolar handpiece. The supraorbital rim of the orbit was treated with the bipolar handpiece at a 52-W fluence for 60 seconds. An on-off ironing technique was employed, moving in the medial to lateral direction. Four treatments were administered to each patient at 4- to 6-week intervals. Clinical photographs were taken one month posttreatment and compared with pretreatment photographs. The patients and an independent physician-evaluator noted significant improvements (Figures 1-4).

All patients reported significant clinical improvement. Furthermore, an independent physician-evaluator rated improvements as 40% to 65%.

Based on these case reports, we conclude that the Accent^{XL} RF device safely and effectively treats rhytides

and lax skin. A standardized total energy-delivered protocol causes reproducible treatment results. In addition, it allows the treatment session to flow smoothly. We have used this treatment protocol in additional patients, and significant clinical improvement continues to be achieved. Further studies are needed with more patients, more treatment sessions, and longer follow-ups to assess optimal treatment parameters.

REFERENCES

1. Friedman DJ, Gilead LT. The use of hybrid radiofrequency device for the treatment of rhytides and lax skin. *Dermatol Surg*. 2007;33:543-551.
2. Alexiades-Armenakas MR, Dover JS, Arndt KA. The spectrum of laser skin resurfacing: nonablative, fractional, and ablative laser resurfacing. *J Am Acad Dermatol*. 2008;58:719-737.
3. Alexiades-Armenakas M, Dover JS, Arndt KA. Unipolar versus bipolar radiofrequency treatment of rhytides and laxity using a mobile painless delivery method. *Lasers Surg Med*. 2008;40:446-453.
4. Hardaway CA, Ross EV. Nonablative laser skin remodeling. *Dermatol Clin*. 2002;20:97-111.
5. Sadick NS, Makino Y. Selective electro-thermolysis in aesthetic medicine: a review. *Lasers Surg Med*. 2004;34:91-97.
6. Kim KH, Geronemus RG. Nonablative laser and light therapies for skin rejuvenation. *Arch Facial Plast Surg*. 2004;6:398-409.
7. Mayoral FA. Skin tightening with a combined unipolar and bipolar radiofrequency device. *J Drugs Dermatol*. 2007;6:212-215. ■