

# *Fractional CO<sub>2</sub> laser in the treatment of facial scars in children*

**Moshe Lapidoth, Shlomit Halachmi,  
Sarit Cohen & Dan Ben Amitai**

**Lasers in Medical Science**


ISSN 0268-8921

Volume 29

Number 2

Lasers Med Sci (2014) 29:855-857

DOI 10.1007/s10103-013-1305-6



**Your article is protected by copyright and all rights are held exclusively by Springer-Verlag London. This e-offprint is for personal use only and shall not be self-archived in electronic repositories. If you wish to self-archive your article, please use the accepted manuscript version for posting on your own website. You may further deposit the accepted manuscript version in any repository, provided it is only made publicly available 12 months after official publication or later and provided acknowledgement is given to the original source of publication and a link is inserted to the published article on Springer's website. The link must be accompanied by the following text: "The final publication is available at [link.springer.com](http://link.springer.com)".**

# Fractional CO<sub>2</sub> laser in the treatment of facial scars in children

Moshe Lapidoth · Shlomit Halachmi · Sarit Cohen · Dan Ben Amitai

Received: 4 January 2013 / Accepted: 5 March 2013 / Published online: 26 March 2013  
© Springer-Verlag London 2013

**Abstract** Facial scars in children have a profound psychosocial impact and require early and aggressive treatment. In this age group in particular, however, attention must be placed on the methodology so as not to trigger additional trauma—whether physical or emotional—as a sequela to the treatment. We assess the safety and efficacy of fractional CO<sub>2</sub> in a prospective study of pediatric facial scars from various etiologies. Twenty four children, age 2–16 years, underwent fractional CO<sub>2</sub> laser resurfacing. Recovery, clinical response, and adverse events were monitored at 3 days, 1 week, 1 month, 2 months, and 6 months. Photographs taken before treatment and 2 months after final treatment were independently evaluated and scored by two physicians. All patients tolerated treatment well, with minimal erythema and edema. The clinical improvement was scored as excellent in 14 patients (58 %), good in 7 (29 %), and fair in 3 (13 %). No cases were graded as poor or worse. No adverse events were noted. The study supports the use of fractional CO<sub>2</sub> resurfacing of pediatric facial scars as well tolerated and effective. Given the particularly rapid healing and clinical improvement of pediatric skin, fractional CO<sub>2</sub> treatment should be offered early to mitigate both the physical and psychosocial stigmata of scars as early as possible.

**Keywords** Scar · Fractional photothermolysis · CO<sub>2</sub> laser · Resurfacing · Pediatric

M. Lapidoth (✉) · S. Halachmi · S. Cohen  
Department of Dermatology, Rabin Medical Center, Golda Campus, Petach Tikva 49372, Israel  
e-mail: alapidot@netvision.net.il

M. Lapidoth · D. B. Amitai  
Sackler School of Medicine, Tel Aviv University, Tel Aviv, Israel

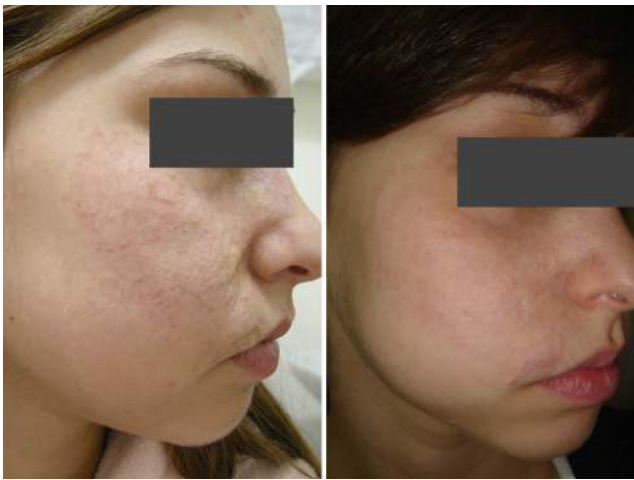D. B. Amitai  
Dermatology Unit, Schneider's Children's Medical Center, Petach Tikva, Israel

## Introduction

Despite the advances in treating scars, pediatric scar management continues to be a major challenge. Facial scars in children are most commonly due to hemangiomas and burns, and less commonly to trauma, infectious diseases, and inflammatory disorders. Facial scars can have a profound psychosocial impact, particularly in children. Surgical reconstruction is sometimes advised, but the most favorable outcome for improving skin texture is achieved by facial resurfacing. Fractional photothermolysis, introduced in 2004, lays down a matrix of energy beams to form an array of microscopic thermal wounds (microscopic treatment zones), to stimulate a therapeutic response in the dermis [1]. Non-ablative fractional photothermolysis at wavelengths of 1,550 and 1,540 nm has been found to be effective for the treatment of scars, but fractional ablative laser has gained popularity in the last years due to its potentially greater efficacy in the treatment of both the dermal and epidermal components of scar tissue [2–7]. The current study describes our clinical experience with carbon dioxide fractional laser resurfacing in the treatment of facial scars in children.

## Methods

The study group consisted of 24 children aged 2–16 years (mean age, 4.2), who were treated in the laser unit of Rabin Medical Center, Israel, between 1 January 2008 and 31 December 2011. All patients presented with mild to severe facial scars. Six patients had Fitzpatrick skin type II, 12 had Fitzpatrick type III, five had Fitzpatrick type IV, and one had Fitzpatrick type V. The causes for the scars were varied: 12 were sequelae of segmental hemangiomas, 6 were burns, 2 were caused by motor vehicle accidents, 2 were sequelae of



**Fig. 1** A 15-year-old girl; facial scar induced by hemangioma. Before and 6 months after two treatments, parameters 25 W and 200 ms pulsed duration

cutaneous leishmaniasis, 1 was incurred during a terrorist attack, and 1 was the residua of pyoderma gangrenosum. All of the scars were mature and stable. None of the patients had undergone prior skin resurfacing. Exclusion criteria were photosensitivity, use of photosensitizing drugs, history of scarring after vaccinations, or active skin disease in the treatment area. Patients' parents were provided with a detailed description of the purpose and possible outcomes of treatment and signed informed consent forms.

In 20 of the 24 patients, treatment was performed under general anesthesia, with an attending anesthesiologist. In four patients with localized lesions, treatment was performed after local infiltration of 1 % lidocaine. The fractional ablative photothermolysis was performed with a  $7 \times 7$  (49 dots) splitting handpiece (Pixel CO<sub>2</sub> Omnifit, Alma Lasers, Israel) which was placed onto a standard CO<sub>2</sub> laser (Sharplan 40C, Lumenis, Israel). Treatments were performed at 25 W and 200 ms pulsed duration, yielding 102 mJ/pulse. Two passes were performed at each treatment session.

Follow-up examinations were performed by the physicians at 3 days, 1 week, 1 month, 2 months, and 6 months after the last treatment to monitor recovery, improvement, and sequelae. Scar improvement and adverse events were recorded and photographs were taken with a digital camera (Nikon D90 Tokyo, Japan). Pretreatment and 2-month photographs were

independently evaluated and compared either by a plastic surgeon and a dermatologist or by two dermatologists, who graded the results on a five-point scale: excellent, 75–100 % textural improvement; good, 50–75 % improvement; fair, 25–50 % improvement; poor, <25 % improvement; or worse, final outcome worse than the pretreatment.

## Results

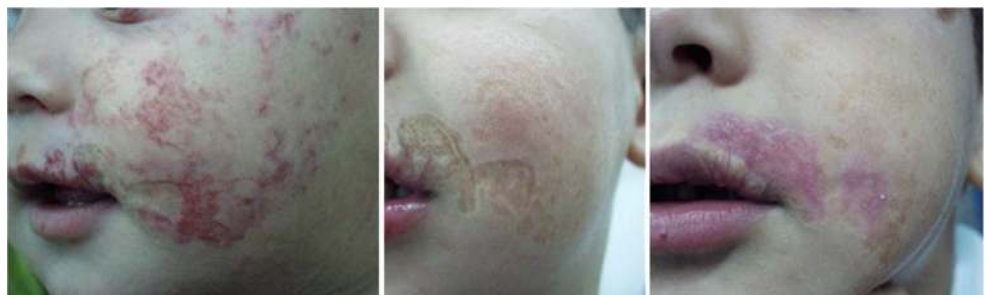The treatment was well tolerated by all patients. The immediate skin reaction consisted of erythema and mild edema, accompanied by some sensation of burning but not significant pain. Erythema lasted 7–18 days (mean,  $9.2 \pm 2.2$  days), while edema resolved more quickly. No permanent adverse outcomes were noted. Patients underwent one to three treatments (mean, 1.8).

All 24 patients returned for the 2-month clinical assessment. Evaluation of the outcome was rated excellent in 14 patients (58 %) and good in 7 (29 %), fair in 3 (13 %). No cases were graded as poor or worse. Representative before and after photographs are presented in Figs. 1 and 2. Evaluation of 18 of the patients who presented for follow-up 6 months after final treatment revealed that clinical results were maintained, significant change in the skin texture. No pigmentary changes were noted at any timepoint.

## Conclusion

The present study reports the outcome of 24 children with facial scars treated with ablative fractional CO<sub>2</sub> laser photothermolysis. Although confluent ablative resurfacing with the CO<sub>2</sub> or Er:YAG laser remains the gold standard in skin rejuvenation, it is associated with considerable downtime and a risk of prolonged erythema, infection, scarring, and delayed hypopigmentation [8–11]. Moreover, it is painful and usually requires general anesthesia. In the search for alternatives that would also promote some collagen regrowth, researchers first turned to nonablative and intense pulsed light lasers [12, 13]. These were found to be safe but limited in efficacy, and the results were not comparable to ablative resurfacing.

**Fig. 2** A 2-year-old girl at time of CO<sub>2</sub> treatment; facial scar induced by hemangioma. Original hemangioma, scar before and 3 months after one treatment, parameters: 25 W and 200 ms pulsed duration





In 2004, Manstein et al. introduced fractional photothermolysis to bridge the gap between ablative and nonablative resurfacing [1]. Resurfacing with a 1,550 nm non-ablative laser using an array of microscopic thermal wounds proved effective, and downtime and morbidity were minimal. However, the procedure required multiple sessions and local anesthesia, and the results were sometimes variable [2, 14–16]. Fractional ablative lasers soon followed and appear to provide better epidermal textural effects [11, 17–22]. These are anticipated to have particular benefit in mature scars, in which the epidermal and dermal pathology has been fixed, and in which removal and regeneration of tissue are required.

It is noteworthy that neither hyperpigmentation nor hypopigmentation, both particularly troublesome sequelae of ablative laser resurfacing, were not noted in these patients, even at 6 months post treatment. This is likely explained by the microscopic pattern of injury induced by the CO<sub>2</sub> laser, which induced minimal inflammation and therefore no clinically evident pigmentary changes.

The approach used in the current study also warrants mention. The treatment was done within a public hospital, using an existing CO<sub>2</sub> laser designed for confluent ablation, which was adapted to fractional photothermolysis by the addition of a retrofitted handpiece, which splits the beam into a fractional pattern to deliver the desired matrix of microablation zones. This approach provides a cost-effective method of maximizing the clinical utility of existing equipment.

The current study demonstrates clear clinical efficacy in the treatment of facial scars with fractional CO<sub>2</sub>, regardless of the etiology of the scar. It is important to note that pediatric skin is known to respond briskly and heal well to treatments, a factor which likely contributes to the success of treatment in this age group. The very high level of clinical efficacy, even in fully mature scars, supports the use of the approach even after scars have are considered to be static, a condition that might have suggested reduced plasticity of tissue. Based on these results, we recommend early intervention in pediatric facial scars, to maximize the clinical benefit and to mitigate social stigmata as early as possible.

## References

- Manstein D et al (2004) Fractional photothermolysis: a new concept for cutaneous remodeling using microscopic patterns of thermal injury. *Lasers Surg Med* 34(5):426–438
- Geronemus RG (2006) Fractional photothermolysis: current and future applications. *Lasers Surg Med* 38(3):169–176
- Alster TS, Tanzi EL, Lazarus M (2007) The use of fractional laser photothermolysis for the treatment of atrophic scars. *Dermatol Surg* 33(3):295–299
- Chrastil B et al (2008) Second-generation 1,550-nm fractional photothermolysis for the treatment of acne scars. *Dermatol Surg* 34(10):1327–1332
- Gold MH, Heath AD, Biron JA (2009) Clinical evaluation of the SmartSkin fractional laser for the treatment of photodamage and acne scars. *J Drugs Dermatol* 8(11 Suppl):s4–s8
- Vasily DB et al (2009) Non-ablative fractional resurfacing of surgical and post-traumatic scars. *J Drugs Dermatol* 8(11):998–1005
- Schulz KK, Walling HW (2010) Fractional photothermolysis improves a depressed alar scar following Mohs micrographic surgery. *J Drugs Dermatol* 9(1):66–67
- Ross EV et al (2001) One-pass CO<sub>2</sub> versus multiple-pass Er:YAG laser resurfacing in the treatment of rhytides: a comparison side-by-side study of pulsed CO<sub>2</sub> and Er:YAG lasers. *Dermatol Surg* 27(8):709–715
- Alster TS (2002) One-pass CO<sub>2</sub> versus multiple-pass Er:YAG laser resurfacing in the treatment of rhytides: a comparison side-by-side study of pulsed CO<sub>2</sub> and Er:YAG lasers. *Arch Facial Plast Surg* 4(4):273–274
- Tanzi EL, Alster TS (2003) Single-pass carbon dioxide versus multiple-pass Er:YAG laser skin resurfacing: a comparison of postoperative wound healing and side-effect rates. *Dermatol Surg* 29(1):80–84
- Alexiades-Armenakas MR, Dover JS, Arndt KA (2008) The spectrum of laser skin resurfacing: nonablative, fractional, and ablative laser resurfacing. *J Am Acad Dermatol* 58(5):719–737, quiz 738–40
- Herne KB, Zachary CB (2000) New facial rejuvenation techniques. *Semin Cutan Med Surg* 19(4):221–231
- Menaker GM et al (1999) Treatment of facial rhytids with a nonablative laser: a clinical and histologic study. *Dermatol Surg* 25(6):440–444
- Rokhsar CK, Fitzpatrick RE (2005) The treatment of melasma with fractional photothermolysis: a pilot study. *Dermatol Surg* 31(12):1645–1650
- Marra DE et al (2006) Systemic toxicity from topically applied lidocaine in conjunction with fractional photothermolysis. *Arch Dermatol* 142(8):1024–1026
- Rahman Z, Alam M, Dover JS (2006) Fractional laser treatment for pigmentation and texture improvement. *Skin Therapy Lett* 11(9):7–11
- Dierickx CC et al (2008) Micro-fractional ablative skin resurfacing with two novel erbium laser systems. *Lasers Surg Med* 40(2):113–123
- Lapidoth M, Yagima ME, Odo ME, Odo LM (2008) Novel use of erbium:YAG (2,940-nm) laser for fractional ablative photothermolysis in the treatment of photodamaged facial skin: a pilot study. *Dermatol Surg* 34(8):1048–1053
- Berlin AL et al (2009) A prospective study of fractional scanned nonsequential carbon dioxide laser resurfacing: a clinical and histopathologic evaluation. *Dermatol Surg* 35(2):222–228
- Cho SB et al (2009) The efficacy and safety of 10,600-nm carbon dioxide fractional laser for acne scars in Asian patients. *Dermatol Surg* 35(12):1955–1961
- Gotkin RH et al (2009) Ablative skin resurfacing with a novel microablative CO<sub>2</sub> laser. *J Drugs Dermatol* 8(2):138–144
- Hunzeker CM, Weiss ET, Geronemus RG (2009) Fractionated CO<sub>2</sub> laser resurfacing: our experience with more than, 2000 treatments. *Aesthet Surg J* 29(4):317–322